Osakidetza

ARABAKO UNIBERTSITATE OSPITALEA
HOSPITAL UNIVERSITARIO ARABA

38 CONGRESO SEMCPT
Sociedad Española de Medicina y Cirugía de Pie y Tobillo

Artrodesis Calcaneotibial con clavo de 3ª generación

Experiencia Hospital Universitario Álava

Dr.De los Mozos

Dr. Arguijo

EUSKO JAURLARITZA
GOBIERNO VASCO
OSASUN SAILA
DEPARTAMENTO DE SALUD

Indicaciones:

- NAV astrágalo.
- Rescate de prótesis de tobillo.
- Artritis reumatoide
- Rescate artrodesis Tib-astrag.
- Artropatía de Charcot
- Traumatismos.
- Deformidades severas.

Contraindicaciones:

- Art subastragalina sana
- Falta de stock óseo (calcáneo)
- Deformidad angular severa tibia distal.
- Infección activa.

Knee Surg Sports Traumatol Arthrosc
DOI 10.1007/s00167-015-3548-1

“ Conseguir una artrodesis sólida, no dolorosa con un pie plantígrado; biomecánicamente estable que permita la deambulación”

Taylor et al. American Foot & Ankle. 2015

5º valgo

dorsiflexión neutra

5º rot externa (similar contralateral)

Revisión 11 pacientes

Intervenidos 2014-2016

13 meses seguimiento medio

EVA preIQ/postIQ

AOFAS preIQ/PostIQ

Clavo Phoenix (Zimmer)

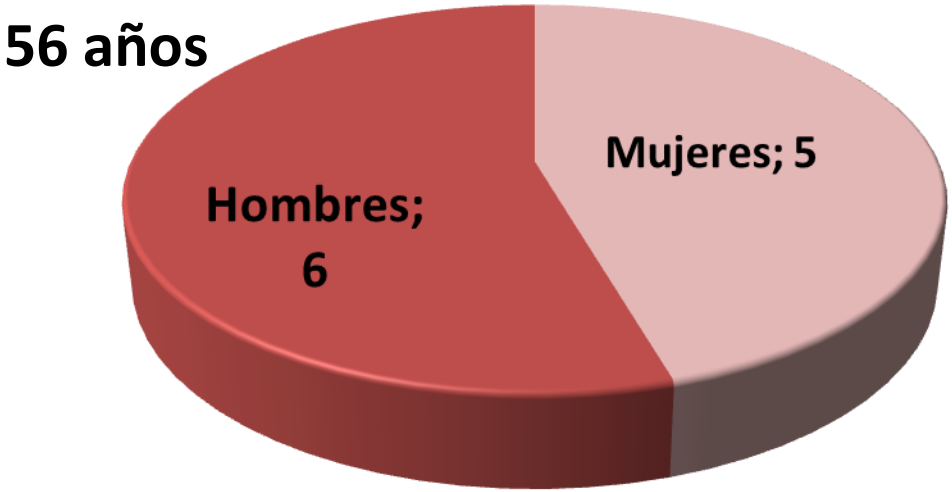

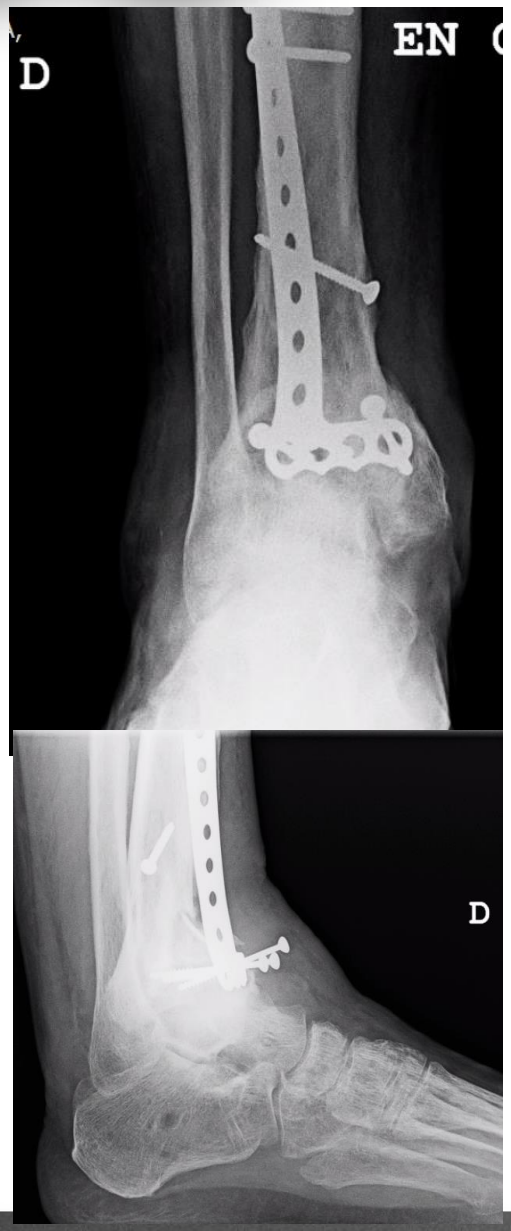
D
EN
D

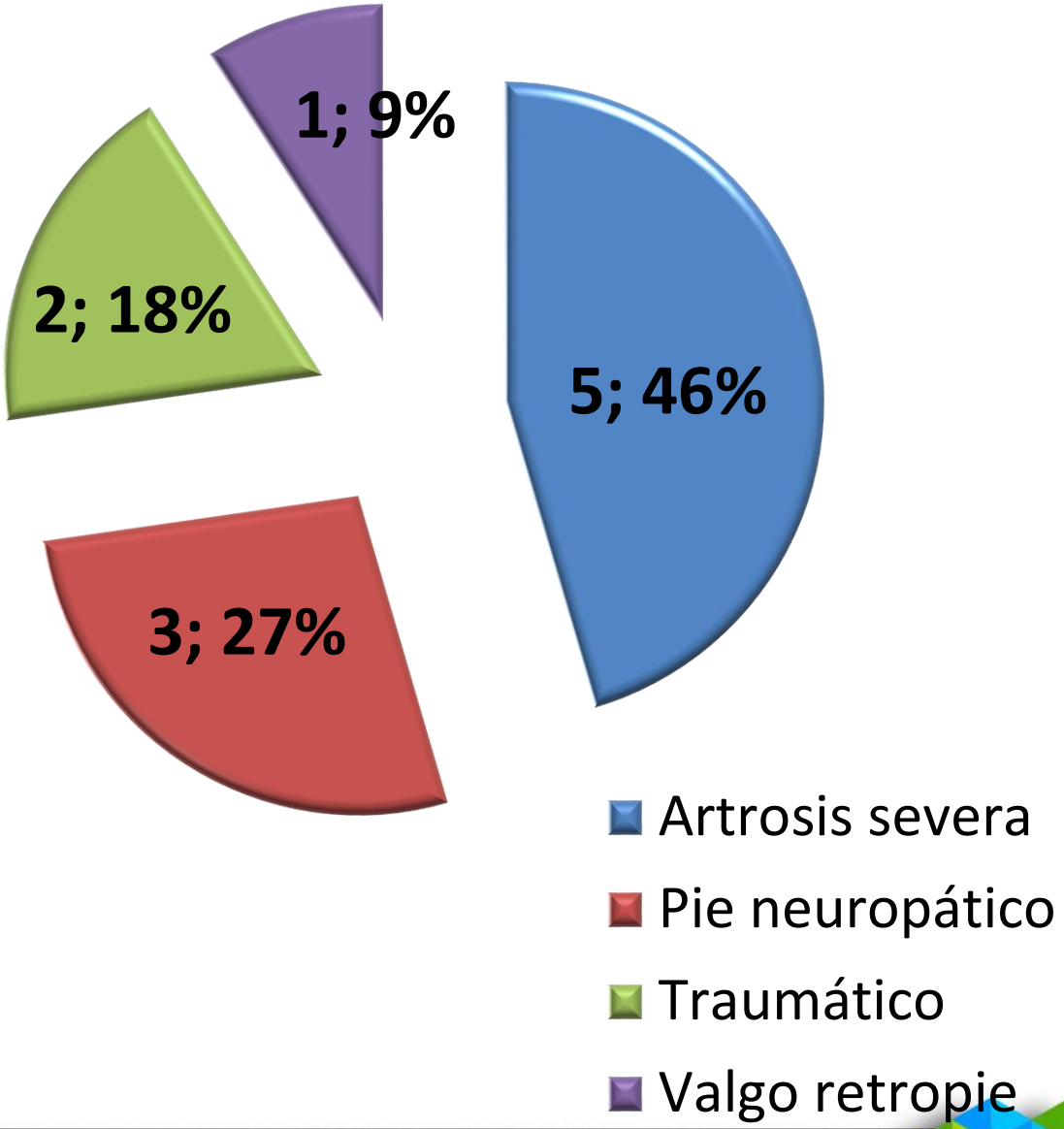
1; 9%
2; 18%
5; 46%
3; 27%
Artrosis severa
Pie neuropático
Traumático
Valgo retropie

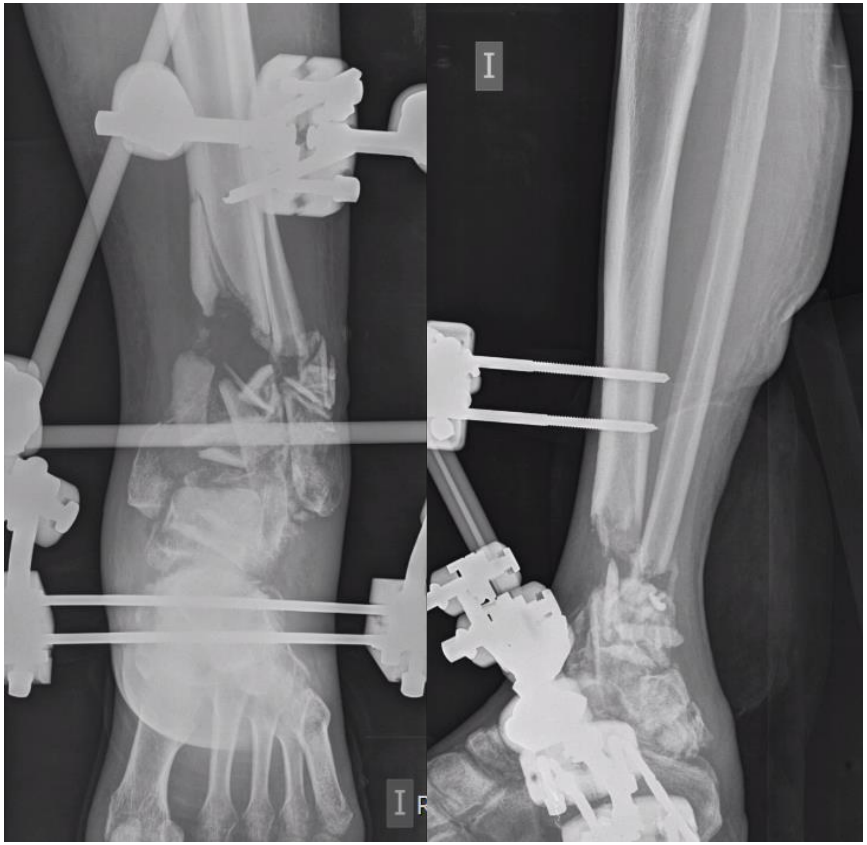

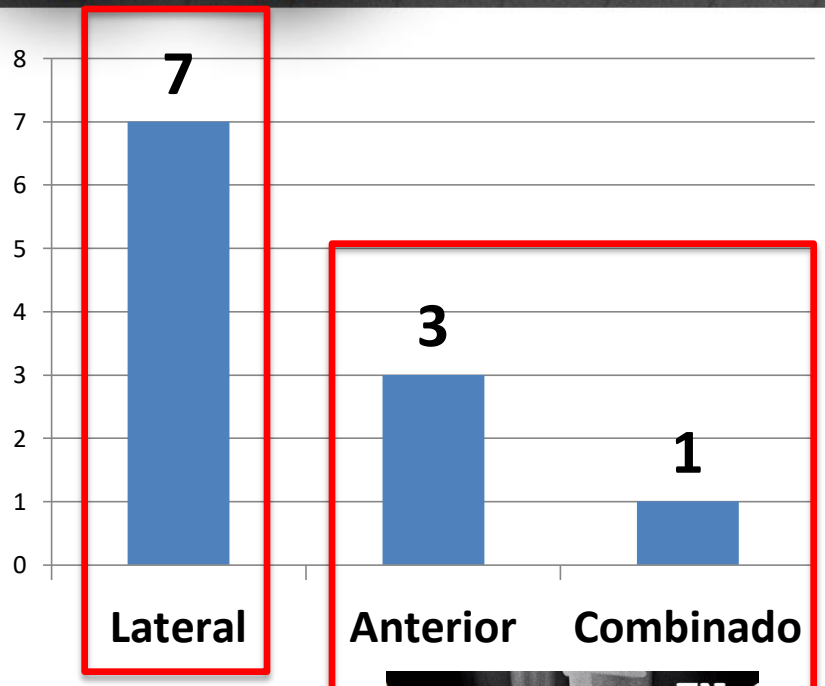
8
7
6
5
4
3
2
1
0
7
3
1
Lateral
Anterior
Combinado

D
EN

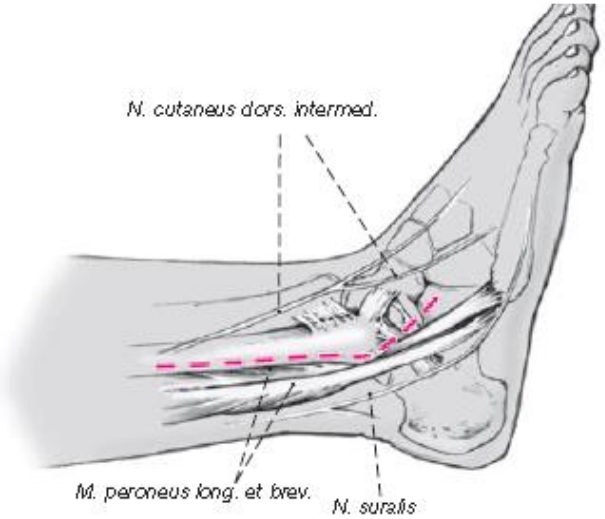
N. cutaneus dors. intermed.
M. peroneus long. et brev.
N. suralis

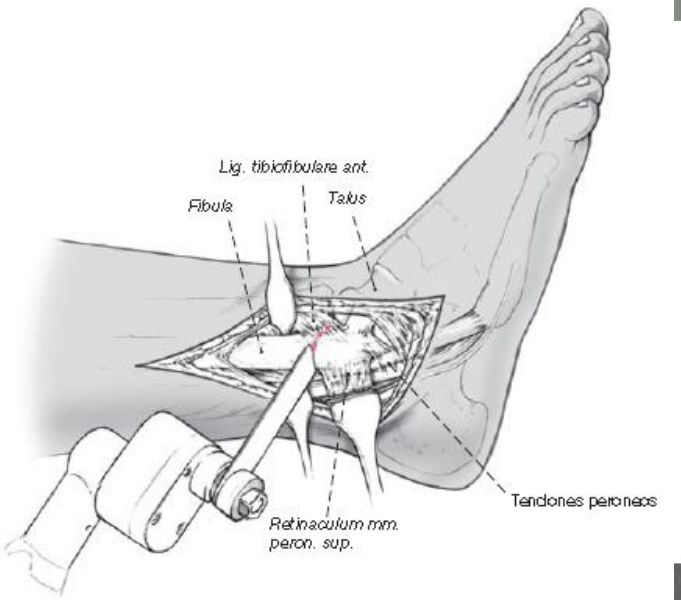
Lig. tibiofibulare ant.
Fibula
Talus
Tendones peroneos
Retinaculum mm.
peron. sup.

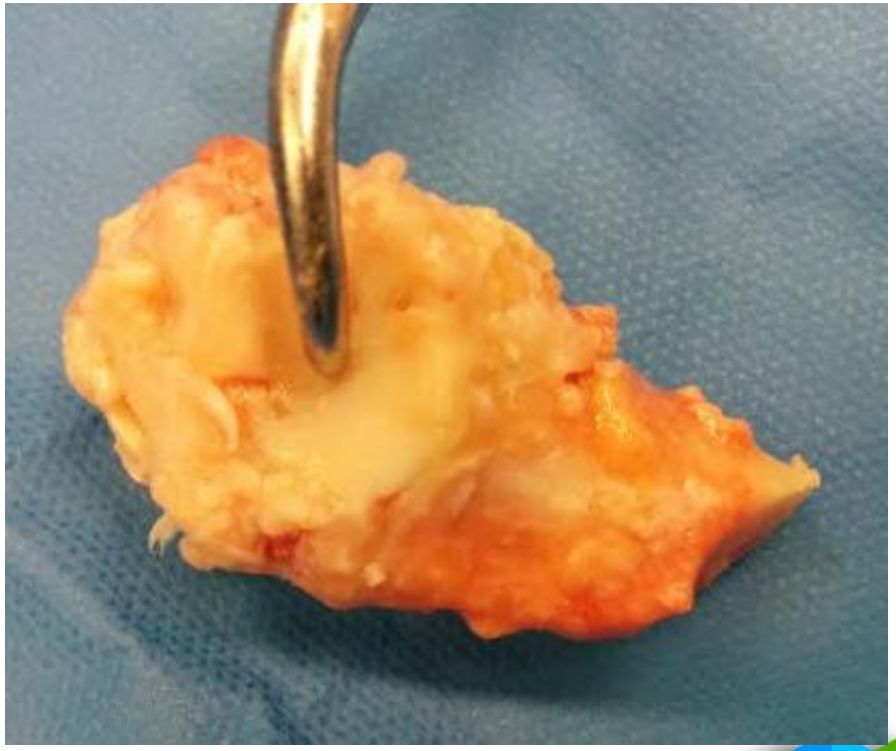

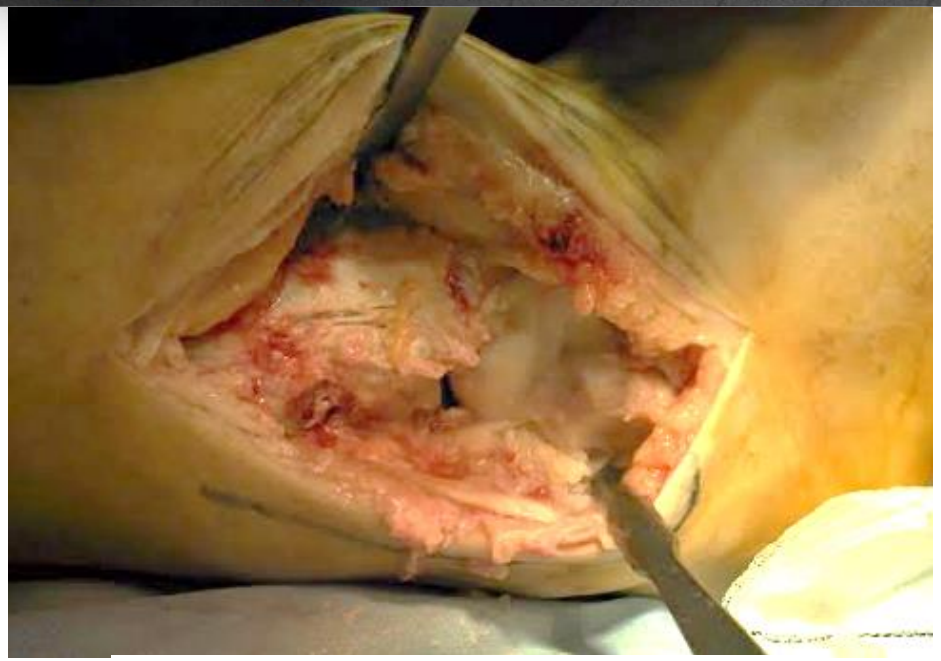

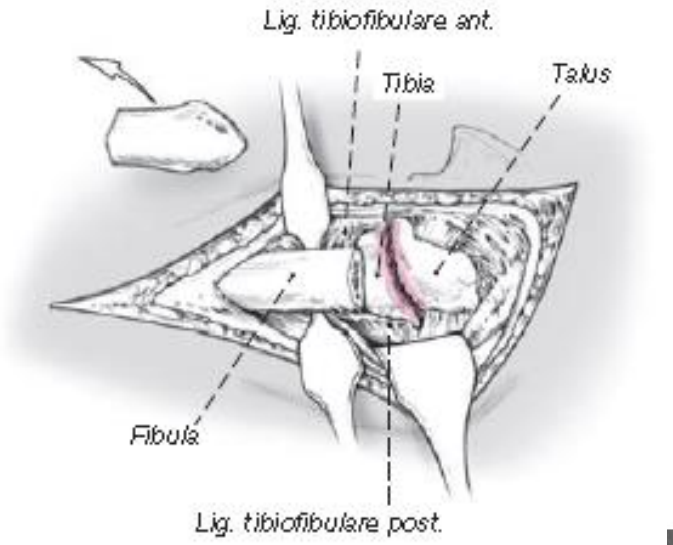
Lig. tibiofibulare ant.
Tibia
Talus
Fibula
Lig. tibiofibulare post.



5,3 días

8 semanas

6-8 semanas

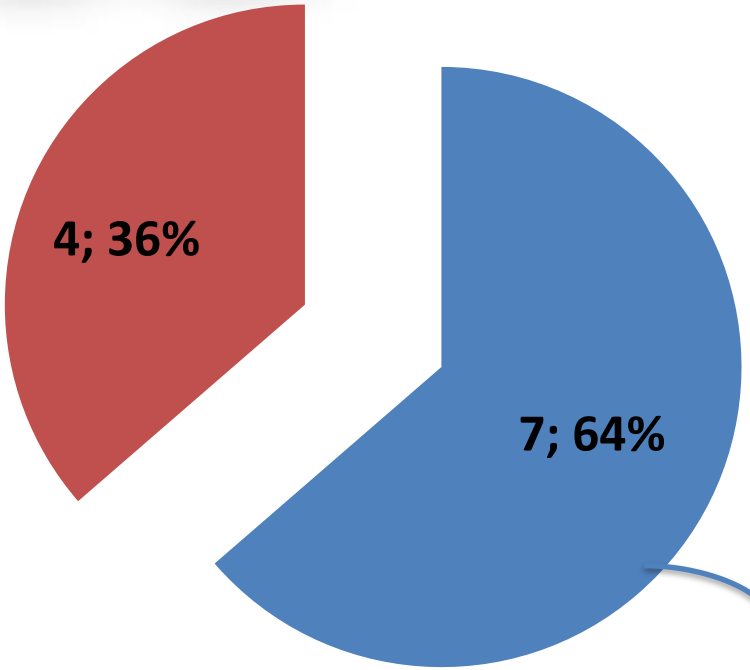
4; 36%
7; 64%



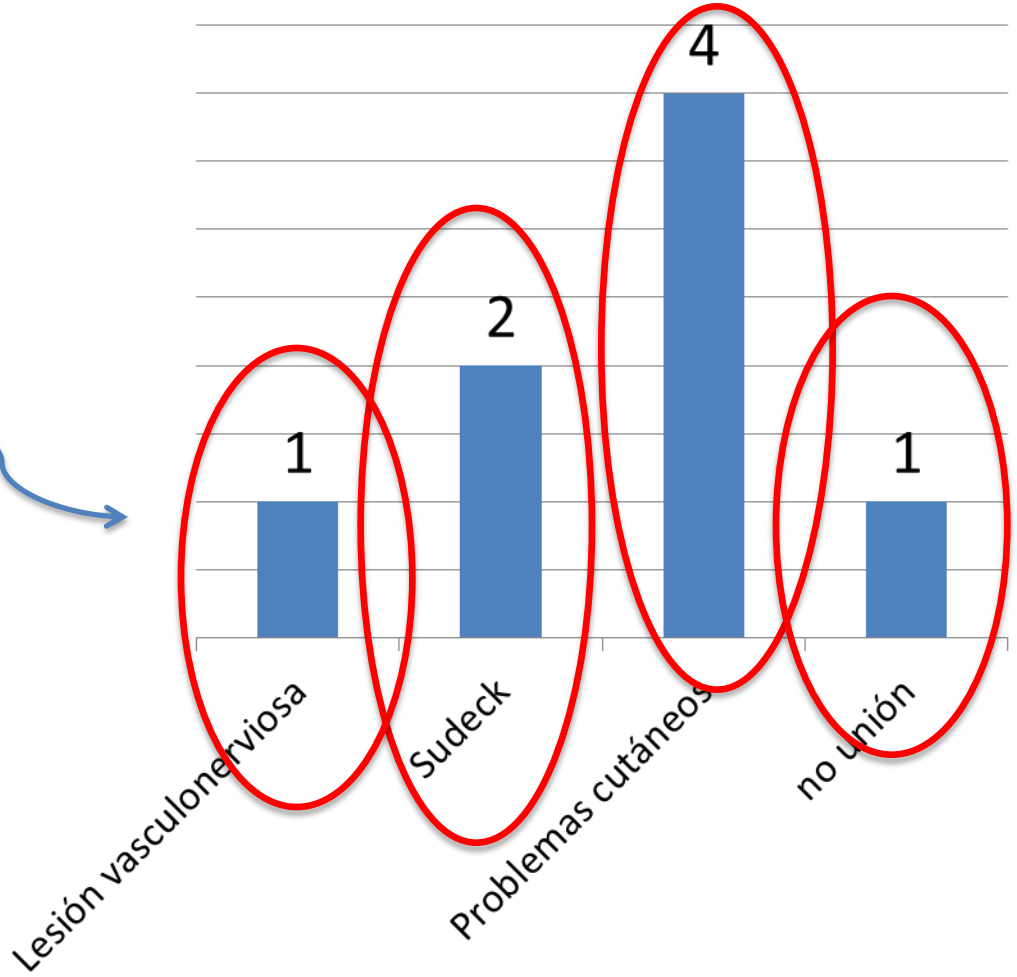
1
2
4
1
Lesión vasculonervviosa
Sudeck
Problemas cutáneos
no unión

SDRC:

Caso 1:

- AOFASpre: 8
- AOFASpost: 28

Caso 2:

- AOFASpre: 39
- AOFASpost: 15

Descriptive	AOFASpre	AOFASpost
Mean	30,36	60,82
Median	30,00	65,00
Standard Deviation	16,37	21,33
Standard Error	4,94	6,43

Paired T-Student Test	
H0:	AOFASpre average= AOFASpost average
HA:	AOFASpre average < AOFASpost average
p-value:	**0,135%**

Reject equality of means

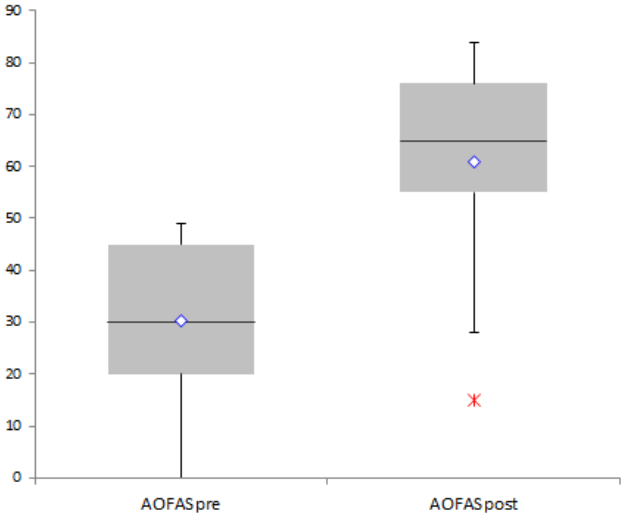

Autor	año	n	Edad	seguim	AOFAS pre	AOFAS post
Chou LB et al	2000	55	53	26m		66
Goebel M et al	2006	29	53	25m	46	71
Tavakkolizadeh A	2006	26	57	26m		66
S.Tejero García et al	2012	55		31m	27,2	67,1
P.Sánchez Gómez	2008	8	60	32m	21,1	88
E.Sánchez-Alepuz	2003	5	38	17m	23,7	70
V.Pellicer-García	2010	15	46	20m	19,8	63,6
HUA	2016	11	56	13m	30,36	60,82



Descriptive	EVApre	EVApost
Mean	8,09	4,45
Median	8,00	5,00
Standard Deviation	2,26	2,50
Standard Error	0,68	0,76

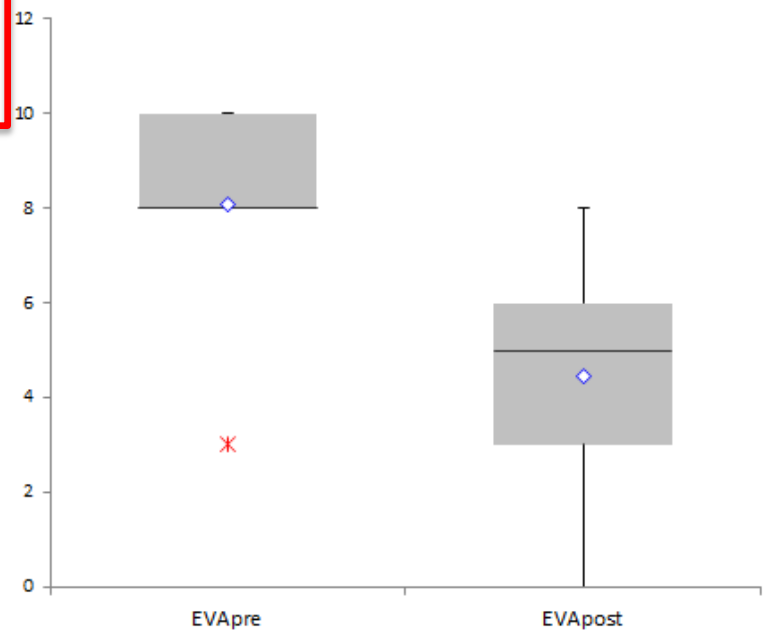

Paired T-Student Test	
H0:	EVApre average= EVApost average
HA:	EVApre average < EVApost average
p-value:	**0,698%**

Reject equality of means

¿Se volvería a intervenir?

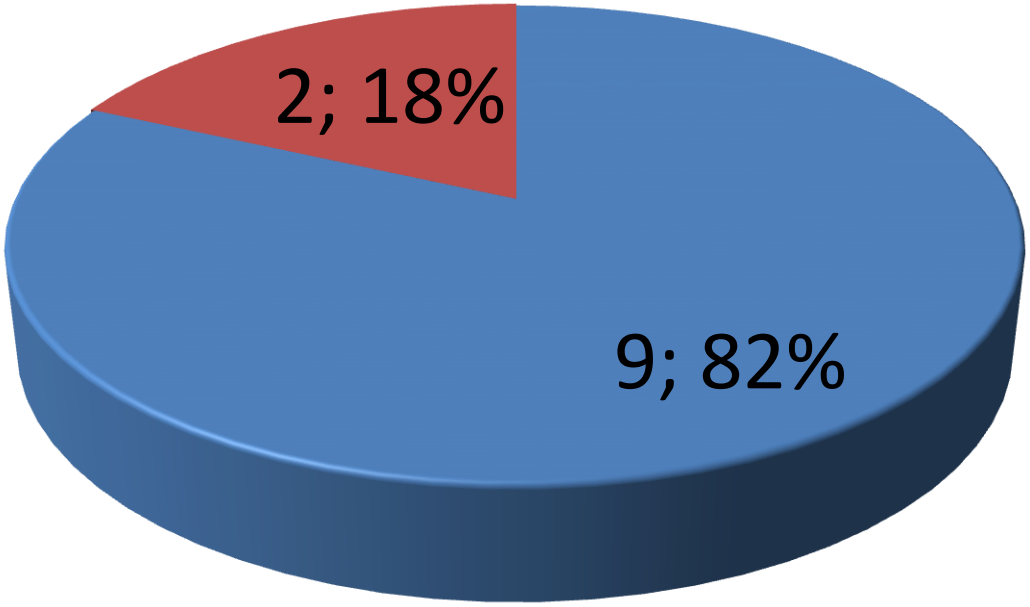

CONCLUSIONES:

- Técnica exigente.
- No exenta de complicaciones
- Método de rescate, no técnica estándar
- Resultado funcional bueno
- Disminución importante del dolor
- Pacientes contentos.

Osakidetza

ARABAKO UNIBERTSITATE OSPITALEA
HOSPITAL UNIVERSITARIO ARABA

Eskerrik asko

Muchas gracias

Esta obra se publica bajo una licencia Creative Commons bajo las siguientes condiciones:
Libre difusión Autorizados Trabajos derivados
Reconocimiento autoría original- Derivados para usos no comerciales - Compartir derivados bajo la misma licencia
Mas información y licencia completa: *http://creativecommons.org/licenses/by-nc-sa/3.0/deed.es*

EUSKO JAURLARITZA
GOBIERNO VASCO
OSASUN SAILA
DEPARTAMENTO DE SALUD

Tibiotalocalcaneal Arthrodesis Nails: A Comparison of Nails With and Without Internal Compression

James Taylor, DO[1], Douglas E. Lucas, DO[2], Aimee Riley, DO[1], G. Alex Simpson, DO[3], and Terrence M. Philbin, DO[4]

Artrodesis tibiotalocalcánea con clavo retrógrado mediante cirugía de mínima incisión. Análisis preliminar de una serie de casos

S. Tejero García, A. Carranza Bencano, J.J. Fernández Torres, G. Castillo Blanco, A. Alegrete Parra, J.R. Fernández Velázquez, P. García Parra
Universidad de Sevilla. Facultad de Medicina. Servicio Andaluz de Salud. Hospital Universitario Virgen del Rocío. Sevilla

Tibiotalocalcaneal arthrodesis in treatment of hindfoot pain and deformity

A. Tavakkolizadeh*, M. Klinke, M.S. Davies
Department of Orthopaedics, Guy's & St. Thomas' Hospitals, London, UK

Received 14 June 2005; received in revised form 17 October 2005; accepted 29 November 2005

Artrodesis tibioastragalina con clavo tibial de compresión

Thomas Mückley[a], Gunther Hoffmann[a] y Volker Bühren[b]

Retrograde Intramedullary Nailing in Tibiotalocalcaneal Arthrodesis: A Short-Term, Prospective Study

Michael Goebel, MD,[1] L. Gerdesmeyer, MD,[1] T. Mückley, MD,[2] M. Schmitt-Sody, MD,[3] P. Diehl, MD,[1] J. Stienstra, DPM,[4] and V. Bühren, PhD[2]

Artrodesis tibioastragalocalcánea con clavo intramedular retrógado

P. Sánchez Gómez*, J.E. Salinas Gilabert, F. Lajara Marco y J.A. Lozano Requena

Servicio de Cirugía Ortopédica y Traumatología, Hospital Vega Baja, Orihuela, Alicante, España

Recibido el 19 de agosto de 2008; aceptado el 29 de marzo de 2009
Disponible en Internet el 5 de diciembre de 2009

Tibiotalocalcaneal Arthrodesis

Loretta B. Chou, M.D.[1], Roger A. Mann, M.D.[2], Burt Yaszay, B.S.[1], Stanley C. Graves, M.D.[3], William T. McPeake III, M.D.[4], Sharon M. Dreeben, M.D.[5], Greg A. Horton, M.D.[6], David A. Katcherian, M.D.[7], Thomas O. Clanton, M.D.[8], Richard A. Miller, M.D.[9], John W. Van Manen, M.D.[10]
USA

Artrodesis tibiotalocalcánea con clavo retrógrado de reconstrucción

E. Sánchez-Alepuz[a], M. Sánchez-González[b] y E. Martínez-Arribas[b]
[a]*Unidad del Pie y de la Marcha. Clínica Quirón. Valencia.* [b]*Servicio de COT. Hospital Universitari La Fe. Valencia.*

Tibiotalocalcaneal Arthrodesis Using a Dynamically Locked Retrograde Intramedullary Nail

Kevin Pelton, M.D.; Jason K. Hofer, M.D.; David B. Thordarson, M.D.
Los Angeles, CA

Tibiotalocalcaneal arthrodesis using an intramedullary nail: a systematic review

Francesco Franceschi · Edoardo Franceschetti · Guglielmo Torre · Rocco Papalia · Kristian Samuelsson · Jón Karlsson · Vincenzo Denaro

The success of tibiotalocalcaneal arthrodesis with intramedullary nailing – A systematic review of the literature

Shah Jehan, Mohammad Shakeel, Andrew J. F. Bing, Simon Owain Hill

The Robert Jones and Agnes Hunt Orthopaedic Hospital, Oswestry, UK

Surgical Correction of Severe Deformity of the Ankle and Hindfoot by Arthrodesis Using a Compressing Retrograde Intramedullary Nail

Foot & Ankle International®
2014, Vol. 35(4) 360–367
© The Author(s) 2014
Reprints and permissions:
sagepub.com/journalPermissions.nav
DOI: 10.1177/1071100714523270
fai.sagepub.com

James W. Brodsky, MD[1], Gregorio Verschae, MD[2], and Shay Tenenbaum, MD[1,3]

Biomechanical Comparison of Intramedullary Nail and Blade Plate Fixation for Tibiotalocalcaneal Arthrodesis

Uosife Alfahd, MD, Sandra E. Roth, MSc, David Stephen, MD, FRCS(C), and Cari M. Whyne, PhD